



Case Report

Management of dislodged crown using split cast metal post and core: A case report

Vishal Srivastava¹, Rishika Yadav Suvarna¹, Devendra Chopra¹, Abhishek Gaur¹, Sumit Kumar Misra¹, Pratibha Yadav¹

¹Department of Prosthodontics and Crown & Bridge, Saraswati Dental College and Hospital, Lucknow, Uttar Pradesh, India.

*Corresponding author:

Vishal Srivastava,
Department of Prosthodontics
and Crown & Bridge, Saraswati
Dental College and Hospital,
Lucknow, Uttar Pradesh, India.

drvishalsrivastava463@gmail.com

Received: 07 January 2024

Accepted: 27 June 2024

Published: 23 July 2024

DOI

10.25259/AJOHAS_1_2024

Quick Response Code:



ABSTRACT

Across diverse cultures, the practice of restoring lost tooth structure has endured through generations. It is widely understood that merely undergoing quality endodontic therapy is not sufficient to fully restore a severely weakened tooth with pulpal disease. Equally crucial is ensuring post-endodontic restoration followed by quality prosthetic rehabilitation. In instances where a tooth is extensively damaged, utilizing a post becomes the preferred course of action post endodontic treatment to preserve the core. The gold standard for the treatment of a severely compromised tooth is recognized as a cast post and core. In this case study, a previously treated maxillary first molar, which had a dislodged fiber post and core along with a porcelain-fused-to-metal (PFM) crown, underwent retreatment with a split cast metal post and core followed by a PFM crown.

Keywords: Split post, Cast metal post and core, Split cast metal post and core

INTRODUCTION

A dislodged crown raises concerns for clinicians, especially if the tooth has received meticulous endodontic treatment and careful restoration. Identifying and addressing the underlying issue is crucial to save the tooth and ensure that it receives the optimal treatment available. The location of the transverse horizontal axis is closer to the posterior teeth, which encounter higher occlusal forces compared to the anterior teeth. Ensuring adequate cuspal coverage in posterior teeth following endodontic treatment is essential to minimize the risk of fracture from occlusal stresses and to withstand potentially harmful lateral forces during excursive movements.^[1] A post, usually fabricated from metal or fiber-reinforced composite resin, inserted and luted into a prepared root canal of a natural tooth, along with a core, enhances retention and resistance for the prosthesis. The main function of the post is to secure a core that supports the final prosthesis.^[1] Post and core systems are essential for protecting against coronal fractures in cases where the residual natural tooth structure is inadequate.

The choice between different types of post systems has been a common concern, which can be simplified by understanding their basic applications.^[2,3] Conventionally, cast post and core has been the preferred method for restoring teeth with minimal remaining structure, and is considered the gold standard for severely damaged teeth. In contrast, prefabricated post systems are available in various materials and involve preformed posts around which a composite core is built, offering time efficiency and satisfactory outcomes. Teeth restored with cast post and core systems demonstrate significantly higher resistance to fractures compared to titanium and glass

This is an open-access article distributed under the terms of the Creative Commons Attribution-Non Commercial-Share Alike 4.0 License, which allows others to remix, transform, and build upon the work non-commercially, as long as the author is credited and the new creations are licensed under the identical terms.

©2024 Published by Scientific Scholar on behalf of Asian Journal of Oral Health and Allied Sciences

fiber post and core systems, primarily due to the superior physical and mechanical properties of cast posts.

Due to the curved roots and non-parallel or elliptical canals commonly found in posterior teeth, posts of this design are not suitable. Instead, using two or more shorter posts in divergent canals enhances retention. Selecting the appropriate post type should consider the canal's shape and size to minimize dentin removal, thereby improving fracture resistance and retention.

The primary objective of employing a split cast post and core is to ensure reliable retention and support for a crown, particularly beneficial in teeth with intricate root canal structures or substantial coronal damage. Through customization of the post and core to suit each root's specific contours, this approach aims to evenly distribute forces and alleviate stress on the tooth structure, thus enhancing the overall longevity of the restoration.

CASE REPORT

A 20-year-old female patient was referred to the Department of Prosthodontics and Crown & Bridge, Saraswati Dental College and Hospital, Lucknow for endodontically treated maxillary first molar (16) with dislodged fiber reinforced post and core retained in porcelain-fused-to-metal (PFM) crown. On clinical examination, the patient had grossly decayed 16, which had to undergo endodontic treatment, followed by prefabricated fiber reinforced post and core with a crown. Tooth was completely asymptomatic and radiographic examination revealed satisfactory obturated canals involving no periapical pathology.

Due to the significant undermining of the palatal wall of the crown [Figure 1], the treatment plan involved restoring the tooth with a custom-made cast post and core followed by a PFM crown. Given the divergent roots, a split cast metal post and core approach was selected.

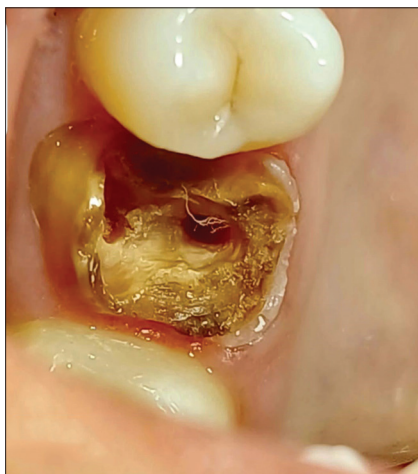

Figure 1: Maxillary first molar.

Procedure

The root canals were prepared using Gates Glidden drills and piezo reamers, and gutta-percha was partially removed from the palatal and mesiobuccal canals, leaving 4–5 mm for apical sealing [Figure 2]. A post pattern was crafted using auto-polymerizing pattern resin (GC pattern resin 1-1), beginning with a lightly lubricated palatal canal [Figure 3]. A thin cylindrical dowel shape was formed using pattern resin, gradually adding resin with a bead brush method until the pattern post fit snugly in the canal. It was repeatedly inserted and removed until the resin reached final polymerization, with undercuts removed using a scalpel. The post was tapered from occlusal to apical. This process was repeated for the mesiobuccal canal. The completed post pattern allowed easy insertion and removal without binding in the canal. Additional pattern resin was used to construct the core, starting with the insertion of the palatal post followed by the mesiobuccal canal. Both were removed after complete polymerization [Figures 4 and 5]. The pattern

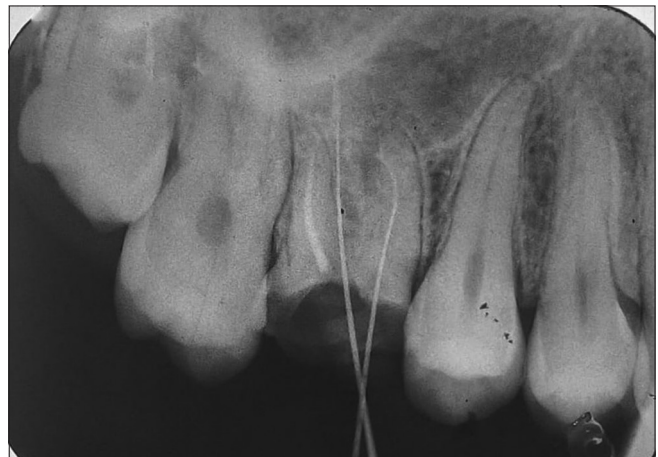

Figure 2: Retrieved gutta-percha 4–5 mm apical to seal from palatal and mesiobuccal canals.

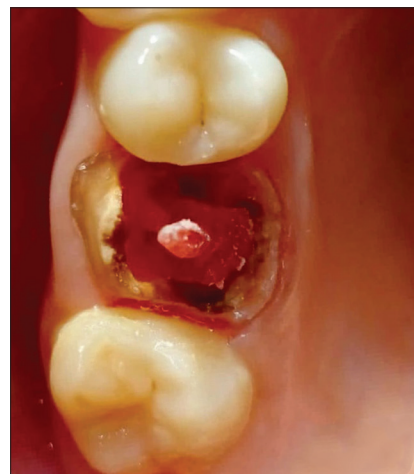

Figure 3: Palatal post pattern.

post and core were reinserted first into the palatal and then the mesiobuccal canal to ensure proper alignment of the

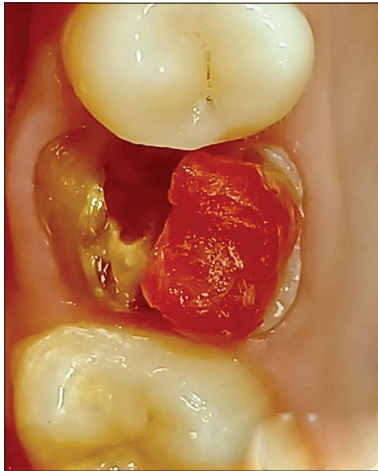

Figure 4: Palatal pattern core buildup.

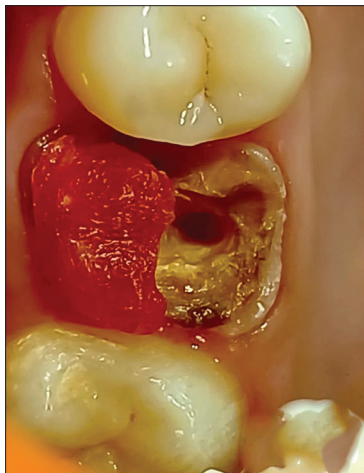


Figure 5: Buccal pattern core buildup.

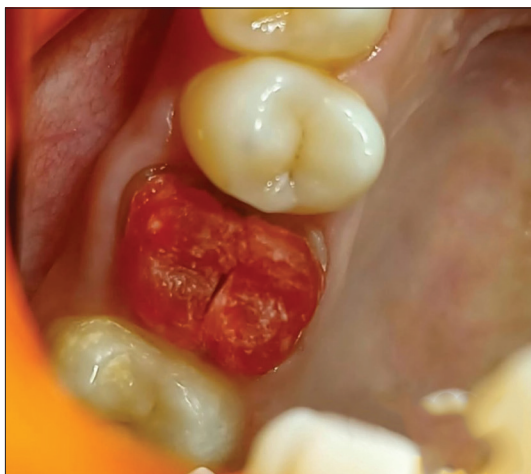

Figure 6: Approximation of buccal and palatal post and core buildups.

split pattern core buildups with the remaining tooth surfaces [Figure 6]. Separate resin patterns for each canal were sprued, invested, and cast in a base metal alloy using conventional lost-wax technique [Figure 7]. After casting, adjustments were made to ensure the cast post and core fit smoothly through the canal pathways [Figure 8]. Each post was individually adjusted to fit securely within its canal, followed by cementation using resin cement once final adjustments were completed [Figures 9 and 10]. Finally, a full coverage PFM crown was fabricated and cemented using type 1 glass ionomer cement [Figure 11].

DISCUSSION

A non-vital tooth typically suffers substantial loss of tooth structure from previous restorations, caries, and access preparations for root canal therapy. Therefore, it requires a restoration and prosthetic treatment that conserves and supports the remaining tooth structure.^[4] The protective feedback system is lost from the teeth when the pulp is

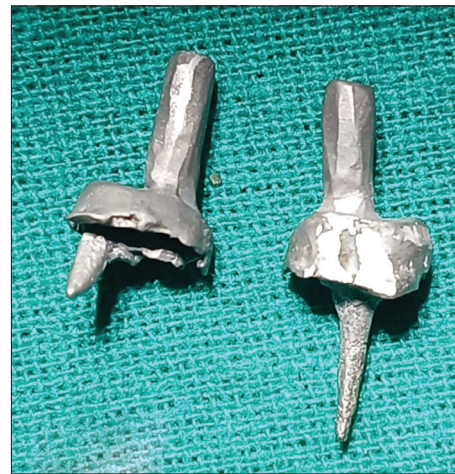

Figure 7: Cast metal post and core.

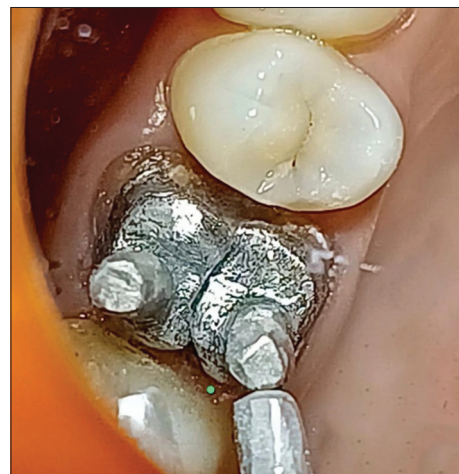

Figure 8: Insertion of cast metal post and core.

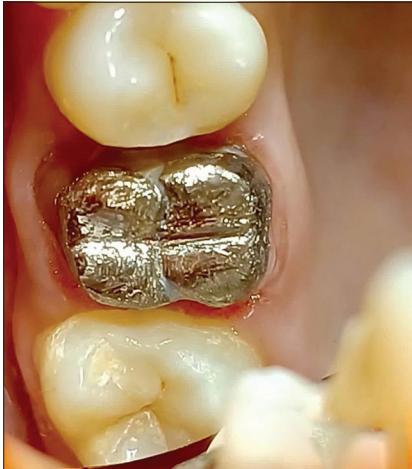

Figure 9: Cementation of cast metal post and core.

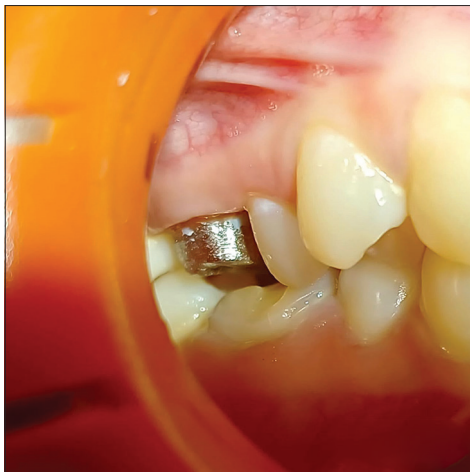

Figure 10: Occlusal clearance for porcelain-fused-to-metal crown.

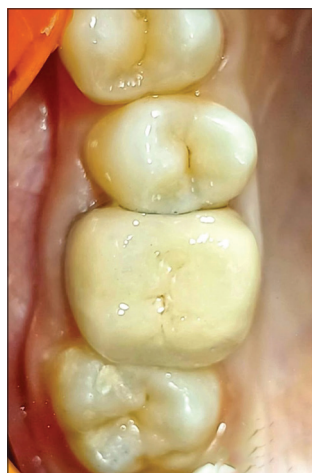

Figure 11: Porcelain-fused-to-metal crown cemented wrt 16.

removed, potentially leading to tooth fractures.^[5] Studies have demonstrated that a significant number of endodontically treated teeth can regain their original function through intraradicular retentive procedures. These procedures encompass one-visit techniques using commercially available prefabricated post systems, as well as more traditional custom-cast post and core devices. Endodontically treated teeth often require the use of posts and cores, especially for posterior teeth with extensive loss of crown structure. Customized posts and cores are recommended in these cases to withstand occlusal forces and precisely fit the prepared root canal. A customized post and cores remain the gold standard for reconstructing severely damaged teeth.^[6,7] A split design in this customized post and core reduces stress during insertion and cementation.^[8] The split can also act as a vent, releasing hydrostatic pressure during post-cementation into the canal, thereby reducing strain during the cementation process. The shape of the canal plays a crucial role in deciding between a custom-made and prefabricated post. A post that closely matches the canal's shape and size can be a more conservative option, requiring less removal of dentin. This approach improves the tooth's ability to resist fractures and enhances the retention of the post. The post and core systems vary in their characteristics and uniqueness, but for clinicians, the selection criteria are crucial as they depend on anatomical considerations, esthetics, and achieving the best possible treatment outcome.^[9]

CONCLUSION

An endodontically treated tooth requires a prosthetic treatment that safeguards and conserves the remaining tooth structure. Customized posts and cores offer favorable outcomes. When a crown becomes dislodged, patients often experience significant psychological impact, particularly when extensive procedures have been performed previously. The decision to utilize a split cast post and core was based on its effectiveness as the optimal treatment to preserve the tooth and restore the patient's confidence, reaffirming trust not only in the clinician but also in the conservative principles of dentistry.

Ethical approval

The Institutional Review Board approval is not required.

Declaration of patient consent

The authors certify that they have obtained all appropriate patient consent.

Financial support and sponsorship

Nil.

Conflicts of interest

There are no conflicts of interest.

Use of artificial intelligence (AI)-assisted technology for manuscript preparation

The authors confirm that there was no use of artificial intelligence (AI)-assisted technology for assisting in the writing or editing of the manuscript and no images were manipulated using AI.

REFERENCES

1. Rosenstiel SF, Land MF, Fujimoto J. Contemporary fixed prosthodontics. 3rd ed. St Louis, Missouri: Mosby; 2001. p. 272-312.
2. Smith CT, Schuman N. Restoration of endodontically treated teeth: A guide for the restorative dentist. Quintessence Int 1997;28:457-62.
3. Sorenson JA, Engleman MJ. Effect of post adaptation on fracture

- resistance of endodontically treated tooth. J Prosthet Dent 1990; 64:419-24
4. Shillenburg HT, Hobo S, Whitsett L, Brachett S. Fundamental of fixed prosthodontics. 3rd ed. Chicago: Quintessence; 1997.
5. Randow K, Glantz P. On cantilever loading of vital and non-vital teeth. Acta Odontol Scand 1986;44:271-7.
6. Morgano SM, Rodrigues AH, Sabrosa CE. Restoration of endodontically treated teeth. Dental Clin N Am 2004;48:397-416.
7. Mentink AG, Meenwissen R, Kayser AF, Malder J. Survival rate and failure characteristics of all the mild post and core restoration. J Oral Rehabil 1993;20:455-61.
8. Brett I, Cohen, Barry LM, Allan S. Comparison of the photoelastic stress for a split shank threaded post. J Prosthet Dent 1994;3:53-5.
9. Lewis R, Smith BG. A clinical survey of failed post retained crowns. Br Dent J 1988;165:95-7.

How to cite this article: Srivastava V, Suvarna Yadav R, Chopra D, Gaur A, Misra SK, Yadav P. Management of dislodged crown using split cast metal post and core: A case report. Asian J Oral Health Allied Sci. 2024;14:11. doi: 10.25259/AJOHAS_1_2024