



Case Series

Management and retraction of rotated canines by different methods: A case series

Sowmya Sinha¹, Masum Mohapatra¹, Sudhanshu Prajapati¹, Aftab Azam¹

¹Department of Orthodontics and Dentofacial Orthopedics, Saraswati Dental College and Hospital, Lucknow, Uttar Pradesh, India.

*Corresponding author:

Sowmya Sinha,
Department of Orthodontics
and Dentofacial Orthopedics,
Saraswati Dental College and
Hospital, 233, Faizabad Road,
Tiwari Ganj, Chinhat, Lucknow,
Uttar Pradesh, India.

sowmyaortho7@gmail.com

Received : 22 September 2022

Accepted : 27 October 2022

Published : 17 November 2022

DOI

10.25259/AJOHAS_19_2022

Quick Response Code:



ABSTRACT

The permanent canines show abnormal eruption most commonly presenting as rotation, ectopic eruption, or impaction. The correction of rotated canines is usually carried out using round NiTi wires during leveling and aligning. In some cases where the conventional techniques fail, a different biomechanical approach is applied. This article describes the correction and retraction of severely rotated canines using three different methods.

Keywords: Rotated canine, Loop, Titanium Molybdenum Alloy (TMA), Canine-protected occlusion, Canine retraction

INTRODUCTION

The permanent canines are the most common teeth to show eruption disturbances due to various reasons such as longest period of development, difficult and longest path of eruption, local factors, and genetic factors.^[1,2] As a result, rotated canines are encountered in clinical practice very often. In cases with mild rotations, using a NiTi round archwire mostly corrects the rotation but in cases of severely rotated canine, a different approach needs to be applied. This article highlights the correction of rotated canines using different mechanics.

CASE SERIES

Case 1

A 21-year-old male reported with a chief complaint of malaligned teeth in the upper front teeth region for 10 years. Intraoral examination revealed Class I molar relationship on both sides whereas the canine relationship was not established on both the sides. A retained deciduous lateral incisor was present on the right side in the maxillary arch and left permanent maxillary canine was rotated distobuccally [Figure 1a]. Fixed mechanotherapy using McLaughlin-Bennett-Trensil (MBT) technique was started following extraction of retained deciduous lateral incisor. 0.0175 NiTi coaxial wire was ligated in the upper arch. In the subsequent appointment, two Beggs' brackets were bonded each on the palatal surface of the maxillary left central incisor and maxillary canine and an elastic chain was placed for the correction of rotated canine [Figure 1b]. The wire sequence followed was 0.012 NiTi, 0.014 NiTi, 0.016 NiTi, and 0.016 × 0.022 NiTi. The rotation of the canine was corrected in 3 months [Figure 1c].

This is an open-access article distributed under the terms of the Creative Commons Attribution-Non Commercial-Share Alike 4.0 License, which allows others to remix, transform, and build upon the work non-commercially, as long as the author is credited and the new creations are licensed under the identical terms.

©2022 Published by Scientific Scholar on behalf of Asian Journal of Oral Health and Allied Sciences

Case 2

A 21-year-old female patient reported with a chief complaint of (1) forwardly placed upper front teeth and (2) irregularly placed teeth in the upper and lower arch for the past 8 years. On intraoral examination, Class I molar relationship with bidental protrusion was present. The canine relationship was not established on either side with the left mandibular canine rotated distobuccally [Figure 2a]. All first premolars were extracted and MBT (0.022 × 0.028 slot) bracket was bonded onto the upper and lower arch. There was no correction in the rotation of the lower left mandibular canine with the use of round NiTi wire alone, so segmental mechanics was used. A box loop was made with 0.016 × 0.022 TMA wire and ligated from the canine to the first permanent molar on the left side in the lower arch [Figure 2b]. After two appointments, the rotation of the

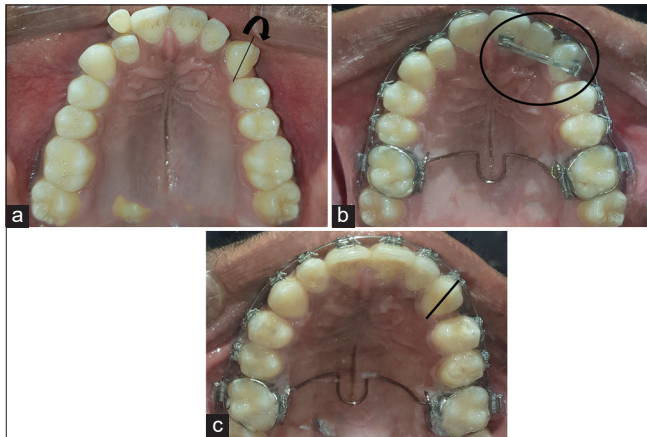


Figure 1: A 21-year-old male patient with Angle's Class I malocclusion with canine relationship not established on the left side along with retained deciduous right lateral incisor and rotations present in maxillary and mandibular arch. (a) Pre-treatment intraoral photograph of maxillary arch shows retained deciduous right lateral incisor and left permanent maxillary canine rotated distobuccally. (b) Beggs' brackets bonded and elastic chain is placed. (c) Occlusal photograph of maxilla 3 months post-placement of e-chain shows correction of rotation of the left permanent canine.

canine was brought in a favorable position for retraction [Figure 2c].

Case 3

A 21-year-old male patient reported with a chief complaint of irregularly placed teeth in the upper and lower jaws for 5 years. Intraoral examination revealed Class I molar and canine relationship bilaterally along with severe crowding in the upper arch and mild crowding in the lower arch. After the extraction of all four first premolars, MBT (0.022 × 0.028 slot) ceramic brackets were bonded in the upper and 0.012 NiTi wire was ligated bypassing the maxillary central incisors. Active tie back was given for retraction of the canine but no improvement was seen. A closed vertical loop was fabricated using 0.016 × 0.022 TMA wire and ligated from the canine to the permanent first molar on both sides in the maxillary arch [Figure 3a-c]. After two activations, the maxillary canines were distalized [Figure 3d] and retraction using active tie back was continued thereafter.

DISCUSSION

The permanent canines are very important teeth in the arch. The eminence of the canine gives esthetic character to the smile. Their high gingival contour helps in determining the smile line. They also play a major role in functional occlusion. In canine guided occlusion, the mandible is guided during the lateral excursive movements and the temporomandibular joint and the dentition are protected. Therefore, when the canine is ectopically erupted or severely rotated, it is essential to bring the canine to its normal position.^[2,3] Several ways have been used to correct the canine rotations. Abuabara *et al.* in 2008 used a segmented fixed TMA box loop for the correction of rotation of single tooth.^[4] The use of TMA wire correction of canine rotation and retraction provides the advantage of controlled force delivery on the tooth and also the benefit of achieving the desired result in a short time period.^[5,6]

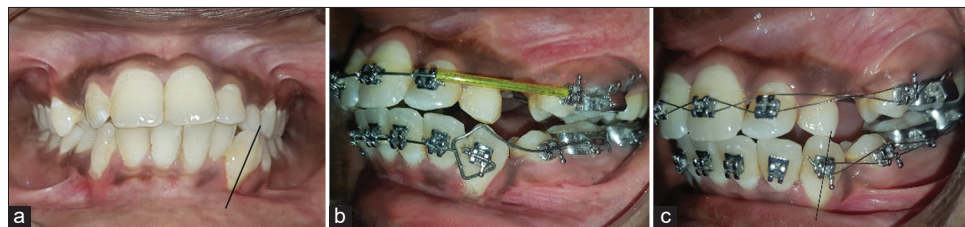

Figure 2: A 21-year-old female patient with Angle's Class I malocclusion with canine relationship not established on both sides along with bimaxillary protrusion and rotations present in both maxillary and mandibular arch. (a) Pre-treatment intraoral photograph shows left mandibular canine rotated distobuccally. (b) Box loop made with 0.016 × 0.022 TMA wire is ligated on the left mandibular canine for segmental approach. (c) Rotation of canine is corrected after two activations.

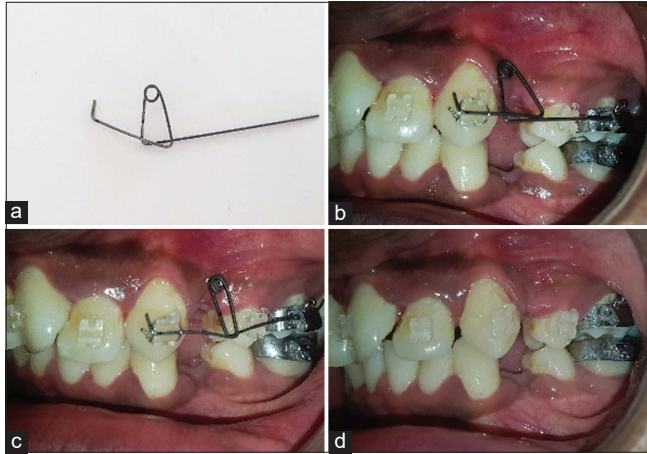


Figure 3: A 21-year-old male patient with Class I molar relationship and canine relationship along with severe crowding in maxillary and mandibular arch. (a) A closed vertical loop is made using 0.016 × 0.022 TMA wire, (b) intraoral picture shows the placement of the closed vertical loop in the left side before activation, (c) activation of the loop is done intraorally, and (d) canine is distalized by 2 mm after 2 months of activation.

CONCLUSION

It can be concluded that in cases where correction of rotated teeth is not possible by conventional means, various other approaches can be applied using loops or two-couple force systems. Every case should be carefully planned and the appropriate biomechanics should be chosen for achieving treatment goals in a shorter duration of time.

Acknowledgment

The researchers would like to thank Dr. Ragni Tandon (Professor and Head, Department of Orthodontics, Saraswati

Dental College, Lucknow) for contributing towards the concept of the article.

Declaration of patient consent

The authors certify that they have obtained all appropriate patient consent.

Financial support and sponsorship

Nil.

Conflicts of interest

There are no conflicts of interest.

REFERENCES

1. Finkelstein T, Shapira Y, Pavlidi AM, Davidovitch M, Blumer S, Schonberger S, *et al.* Canine transposition-prevalence, distribution and treatment considerations among orthodontic patients. *J Clin Pediatr Dent* 2020;44:268-73.
2. Jacoby H. The etiology of maxillary canine impactions. *Am J orthod* 1983;84:125-32.
3. Rinchuse DJ, Kandasamy S, Sciote J. A contemporary and evidence-based view of canine protected occlusion. *Am J Orthod Dentofacial Orthop* 2007;132:90-102.
4. Abuabara A, Yoshida AH, Lago JC. Correction of canine rotation with box loop. *Arch Oral Res* 2008;4:43-7.
5. Burstone CJ, Goldberg AJ. Beta titanium: A new orthodontic alloy. *Am J Orthod* 1980;77:121-32.
6. Burstone CJ. The mechanics of the segmented arch techniques. *Angle Orthod* 1966;36:99-120.

How to cite this article: Sinha S, Mohapatra M, Prajapati S, Azam A. Management and retraction of rotated canines by different methods: A case series. *Asian J Oral Health Allied Sci* 2022;12:13.